



PATIENT

Chicky Garcia

SPECIES

Canine

BREED

Maltipoo

SEX

Female Intact

AGE

9 years

WEIGHT

10.6lbs

INTERPRETED BY

Maggie Machen
Lamy, DVM
DACVIM (Cardiology)

IMAGING PERFORMED BY

Pamela Harrigan,
RDCS

HOSPITAL NAME

Rhode Island Animal
Medical Center

REFERRING VET

Dr. Rogoff

INVOICE

28470

DATE

1/20/23

PRESENTING CLINICAL SIGNS

History: Grade I-II/VI heart murmur. Mammary masses - surgery scheduled. Coughing, Grade 4 dental disease, arthritis. BP: 88,92mmHg. Current medications: Gabapentin 100mg, 1/2 tab every 8-12 hours as needed.
-Abnormal PE/Chem/CBC/UA Results: Platelet count 414.

ECHOCARDIOGRAM FINDINGS

2D, m-mode, color flow and Doppler imaging is available.

Left ventricle: The LV diameter is normal with adequate myocardial function. LV wall thicknesses are normal.

Left atrium: The left atrium is mildly dilated.

Mitral valve: The mitral valve is diffusely thickened with minimal prolapse into the left atrial lumen. Mild mitral regurgitation with a normal velocity.

Aortic valve/aorta: The aortic valve is normal in morphology and mobility. Normal aortic outflow velocity; laminar flow. No aortic insufficiency.

Right ventricle: Normal right ventricular diameter and morphology indicating no overt evidence of pulmonary arterial hypertension.

Right atrium: Mild RA enlargement.

Tricuspid valve: The tricuspid valve appears mildly thickened with mild to moderate tricuspid regurgitation; normal velocity.

Pulmonic valve/pulmonary artery: The pulmonic valve is normal in morphology and mobility. No pulmonic insufficiency. Normal RVOT velocity; laminar flow.

Pericardium/other: No pericardial or pleural effusion noted. No obvious cardiac masses.

Heart rhythm: ECG reveals a sinus rhythm with an average HR of 90bpm.

2-Dimensional Measurements

Ao diam (cm)	1.1
LA diam (cm)	1.4
LA:Ao (Swe)	1.3
IVS thickness (cm)	0.5
LVID diastole (cm)	1.8
PW thickness (cm)	0.5
LVID systole (cm)	1.1
FS (%)	39

Doppler Measurements

PV Vmax (m/s)	0.5
AoV Vmax (m/s)	0.9
MR Vmax (m/s)	5.2
TR Vmax (m/s)	2.4
TR PG (mmHg)	23

INTERPRETATION OF THE FINDINGS

The cause of the murmur is chronic degenerative valve disease causing mild mitral and mild to moderate tricuspid regurgitation. Lack of significant left or right atrial enlargement indicates the current risk for complication is low. The tricuspid leak is greater than the mitral, which is somewhat unusual in the absence of pulmonary hypertension. No additional issues are identified.

Assessment of progression in the future will help predict long term prognosis, which is highly variable at this stage (B1).



PATIENT

Chicky Garcia

SPECIES

Canine

BREED

Maltipoo

SEX

Female Intact

AGE

9 years

WEIGHT

10.6lbs

INTERPRETED BY

Maggie Machen
 Lamy, DVM
 DACVIM (Cardiology)

IMAGING PERFORMED BY

Pamela Harrigan,
 RDCS

HOSPITAL NAME

Rhode Island Animal
 Medical Center

REFERRING VET

Dr. Rogoff

INVOICE

28470

DATE

1/20/23

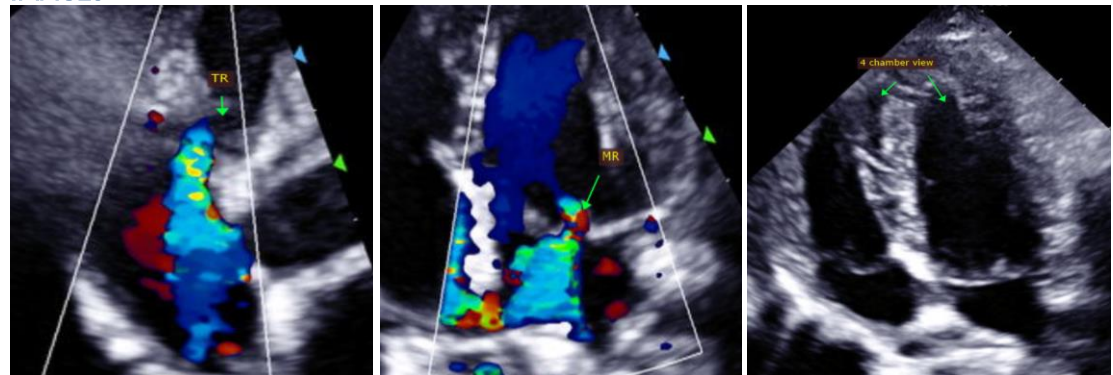
RECOMMENDATIONS

- In a dog without significant left atrial enlargement, no cardiac medications are clearly indicated.
- Omega fatty acid supplementation and mild salt restriction may be of some long-term benefit.
- Anesthetic risk is considered mild if needed. Cardiac protective drug choices (opioid/benzodiazepine premedication, propofol or alfaxalone induction, isoflurane gas) are recommended. Pre-oxygenate for 5-10 minutes prior to induction. Monitor for arrhythmias, hypotension, and hypoxia both intra and post-operatively and intervene as necessary. Mild IV fluid restriction is recommended to avoid fluid overload. Avoid heart rate stimulating drugs such as atropine unless clinically indicated.
- Monitor for development of a cough, labored breathing, exercise intolerance or collapse episodes.

PLAN

- Recommend conservative monitoring with a recheck echocardiogram in 6 months, sooner if any development of clinical signs.

IMAGES



The information and recommendations provided are based on the images presented by the referring veterinarian. No evaluation can be communicated regarding pathology that was not visible in the image/video clips provided.

Thank you for this referral. This report was generated using transcription software, and minor dictation errors may be present. If the clinical or image interpretation does not parallel your findings or if I can be of any further assistance, please contact me.

Maggie Machen Lamy, DVM
 Diplomat of the American College of Veterinary Internal Medicine (Cardiology)
 info@sonopath.com

Echocardiogram performed by: Pamela Harrigan, RDCS
 Pet Animal Ultrasound Service (4paus.com)